
CASE REPORT AND REVIEW OF THE LITERATURE

Complicated shoulder dislocation in the elderly patient

PH Laubscher, MBChB, MMed (Pret), FCS SA(Ortho)

Shoulder Fellow

Upper Limb Unit, Centre Hospitalier Privé St Gregoire, Rennes, France

PG Collin, MD

Shoulder Surgeon

Upper Limb Unit, Centre Hospitalier Privé St Gregoire, Rennes, France

SMA Gain

Physiotherapist

Upper Limb Unit, Centre Hospitalier Privé St Gregoire, Rennes, France

Reprint requests:

Dr PH Laubscher

PO Box 413902

Craighall

2024

South Africa

Tel: +27 82 3302109

phlaubscher@gmail.com

Abstract

Anterior shoulder dislocation in the elderly patient is an injury that is often neglected. Because people are retiring early and living longer than previous generations, the demands for good function remain high despite an increased age. We report on the case of a 66 year-old male patient who had sustained a right anterior shoulder dislocation, greater tuberosity fracture and brachial plexus traction injury. An aggressive approach was followed which led to a satisfactory outcome. We also review opinions expressed in literature on the management of injuries associated with shoulder dislocation in the elderly.

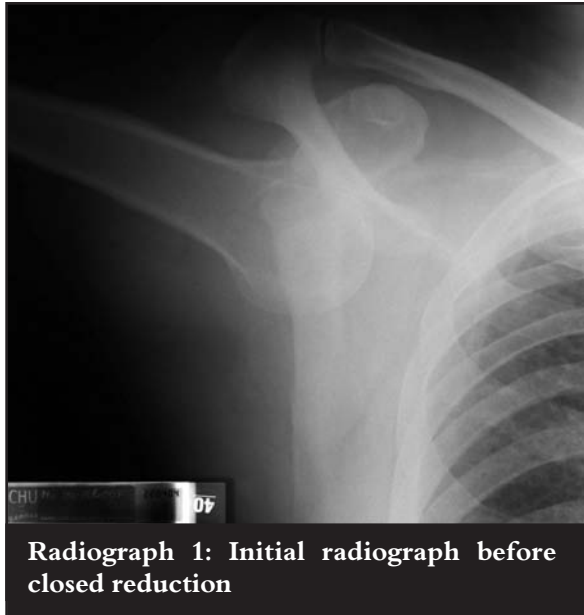
Introduction

Shoulder dislocation in the older patient can be a severely disabling injury. Anterior shoulder dislocation in the younger patient has long been in the spotlight due to its high recurrence rate with subsequent long-term complications. The notion that shoulder dislocation in the elderly occurs less frequently than in younger patients is incorrect. Rowe *et al*¹ showed that the incidence of initial shoulder dislocations before and after 45 years is approximately equal. The recurrence rate is, however, higher in younger patients than older patients.²

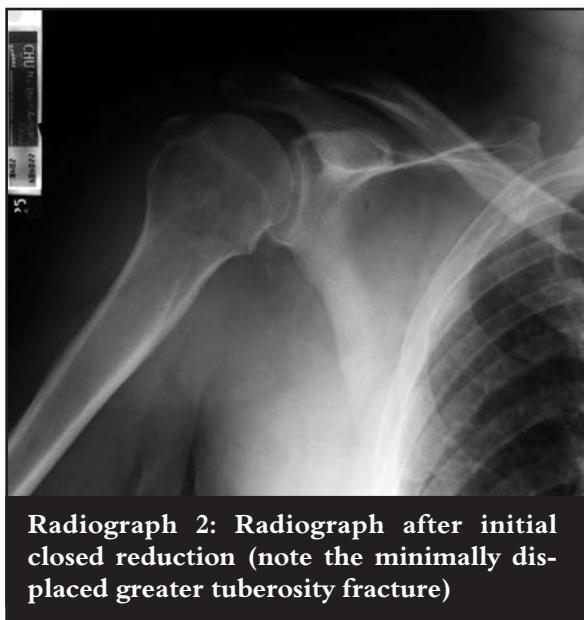
Due to the advances in medical science during the past few decades, older patients live longer and therefore demand more from their joints than the elderly of previous generations.

The types of problems that arise in the older patient who sustains a shoulder dislocation can be significant, and they are prevalent in the older population. Some of these complications can include rotator cuff injury, brachial plexus injury and axillary artery injury, many of which arise due to changes in the physical properties of the tissue that come with age. Rotator cuff tears, especially, can be attributed to these changes. These injuries can lead to severe pain and decreased function.

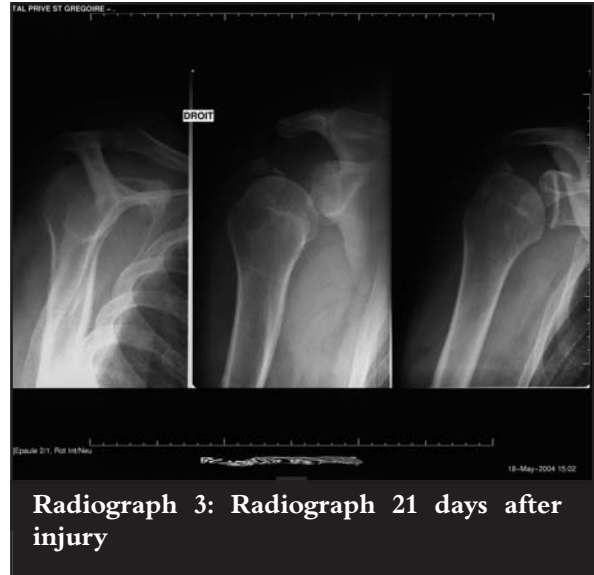The management of associated injuries in elderly patients who have dislocated a shoulder is somewhat controversial. Recommendations vary from predominantly conservative treatment to the more aggressive surgical protocols.^{3,4}



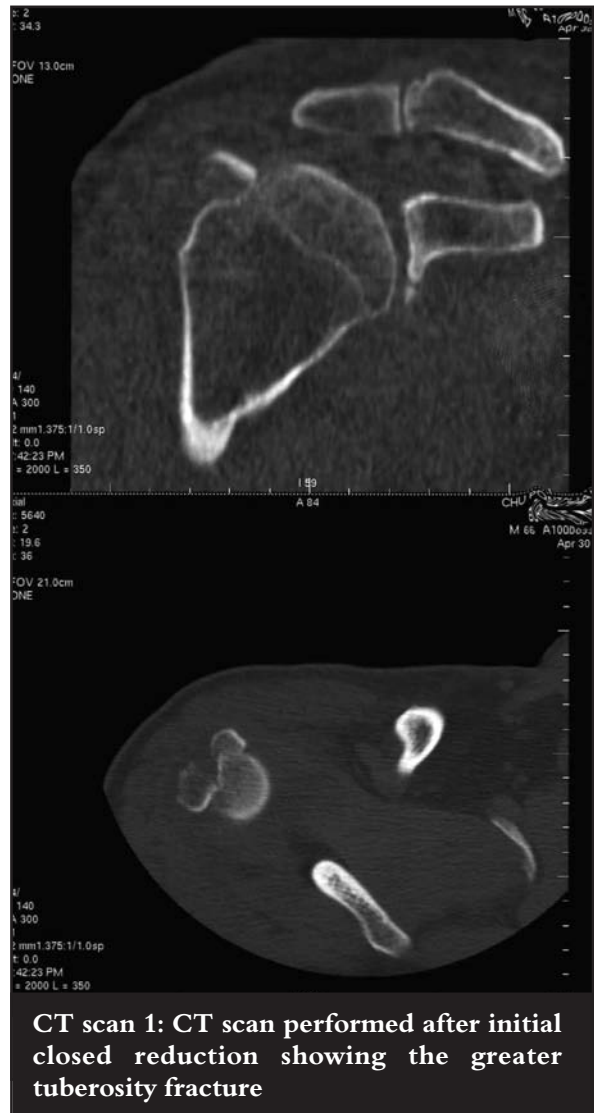Radiograph 1: Initial radiograph before closed reduction



Radiograph 2: Radiograph after initial closed reduction (note the minimally displaced greater tuberosity fracture)



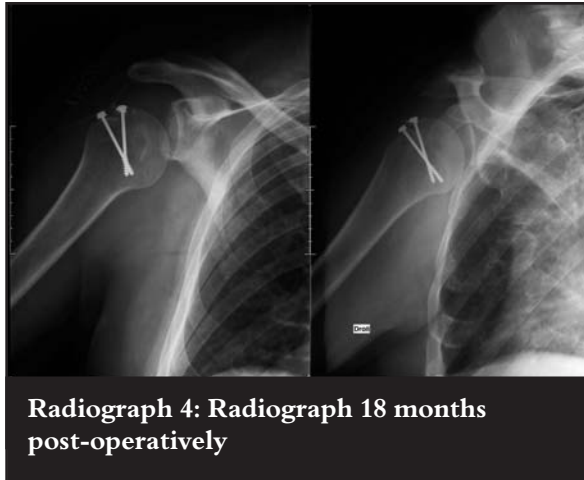Radiograph 3: Radiograph 21 days after injury



CT scan 1: CT scan performed after initial closed reduction showing the greater tuberosity fracture

Case report

A 66 year-old male patient presented to Centre Hospitalier Privé, St Gregoire during May 2004 with the history that he had fallen and had sustained a right shoulder injury. After further questioning, it emerged that he had fallen 21 days prior to his admittance. He attended a local hospital where the diagnosis of anterior shoulder dislocation was made (*Radiograph 1*). The shoulder was reduced by closed reduction and subsequent control radiographs confirmed a successful reduction (*Radiograph 2*). The control radiograph also showed a minimally displaced greater tuberosity fracture. The patient was discharged and informed to follow up at the physiotherapist.



Shortly afterwards, the patient consulted his general practitioner as he was not satisfied with the progress of his recovery. The general practitioner referred the patient to our institution.

The patient presented with the arm immobilised in a sling and complaining of constant pain at rest and severe impairment of the active function of the right shoulder. The patient was in good health and had no other chronic conditions or previous problems with his shoulder.

On clinical examination, it was found that no active motion in the shoulder was possible. The deltoid muscle, when compared to that of the left shoulder, showed signs of atrophy. A full range of passive motion was obtainable. Neurological examination was difficult as no active movements were possible. Anterior-posterior, scapular-lateral and axillary views were obtained, which showed a reduced shoulder joint but a greater tuberosity fracture that had displaced since the initial radiographs (*Radiograph 3*). No other fractures were noted. A CT scan, performed by the initial hospital, confirmed the greater tuberosity fracture (*CT scan 1*). Electromyography was also performed and indicated C5, C6, C7 lesions. They were described as "severe" in the report.

Surgery was performed at 24 days after the initial injury. During the procedure, the greater tuberosity was fixated by two screws and a degenerative rotator cuff was noted.

The arm was immobilised postoperatively with an abduction sling for five weeks. Intensive physiotherapy commenced thereafter. The patient was seen twice weekly by the same therapist. Passive motion was first obtained with the help of massaging, ultrasound, water pool exercises and a home programme. Active motion was increased as rehabilitation progressed.

At the 14-week follow-up, 90 degrees active forward flexion was achieved. Radiographs were also repeated at 18 months, which showed good union of the greater tuberosity (*Radiograph 4*).

The patient was again evaluated clinically for the purpose of this study. Three-and-a-half years after the injury, the patient complained only of general upper-limb pain related to changes in the weather. He stated that he could perform all his normal duties at home and did not feel limited in the activities of daily living.

On examination, we found that the patient could master the full range of passive motion. Active forward flexion of 150 degrees was obtained and active abduction of 132 degrees (*Pictures 1, 2, 3*). A Jobe test was performed and found to be negative. Active abduction with external rotation was also possible by placing the hand on the head. A Constant score was calculated and returned a result of 83/100.

Discussion

Anterior shoulder dislocation in the elderly patient is more common than is generally believed. Gumina *et al*⁵ showed in their series of 545 patients (of all ages) with shoulder dislocations that 20 per cent of these occurred in patients older than 60 years of age.

A host of associated injuries can occur with shoulder dislocations in the elderly. As seen in the case report, these injuries can be severe and often go undiagnosed for a period of time. It is therefore important to be familiar with associated injuries so that examinations and investigations can be directed towards diagnosing these.

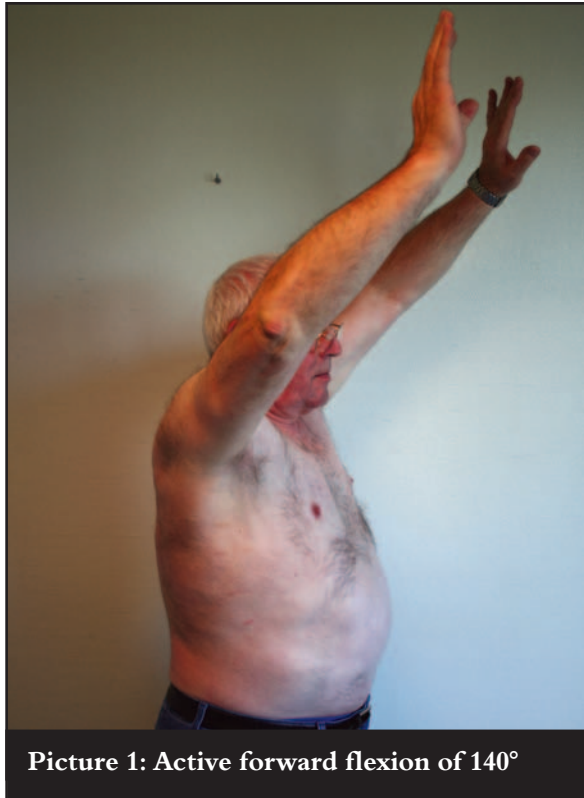
Rotator cuff injury

Stevens⁶ and later Codman⁷ were the first authors to describe the association between rotator cuff tears and shoulder dislocations in older patients. The weaker posterior structures, which include the rotator cuff and greater tuberosity complex, seem to be the reason for this association. The anterior capsuloligamentous complex usually remains intact.

Three-and-a-half years after the injury, the patient stated that he could perform all his normal duties at home and did not feel limited in the activities of daily living

The incidence of rotator-cuff tear after acute dislocation in patients older than 40 ranges from 40% to 85%.^{8,9} In a recent non-randomised, prospective study by Simank,⁴ the authors showed an incidence of 54% in patients older than 40 years, which increased to 100% in patients over 70 years of age.

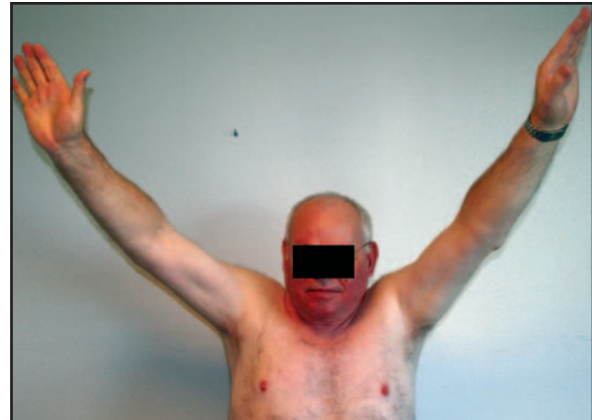The supraspinatus tendon is most commonly affected in shoulder dislocations in the elderly.¹⁰ In their study, the Neviasers¹¹ found a 100% incidence of subscapularis muscle and anterior capsule rupture when **recurrent** shoulder dislocation occurred in the elderly.



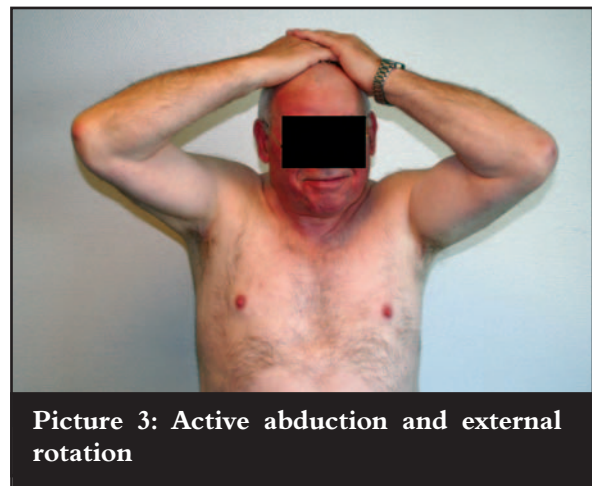Picture 1: Active forward flexion of 140°

The debate remains, though, whether the rotator-cuff tear in many of these patients is entirely due to the dislocation or not. In fact, many patients have underlying partial tears that were present before the dislocation (and caused no symptoms). Berbig *et al*¹² postulate that the acute cuff tears that occur after traumatic shoulder dislocation can be an acute manifestation that is superimposed on a previous chronic rotator-cuff lesion. They bring into question the assumption that the lesion is always the direct consequence of the dislocation.

Literature suggests a “wait and see” approach to these patients. Close clinical follow-up in the period shortly after the initial reduction is suggested so that if the clinical picture does not improve, surgical repair can be performed. Stayner¹³ concluded that significant pain or weakness in the shoulder at 2 to 4 weeks after glenohumeral dislocation is an important reason for an imaging investigation. Penvy⁹ also suggests a protocol in which the shoulder is immobilised for 7 to 10 days and if the shoulder remains painful and weak, a MRI scan should be requested. Our case report supports the importance of such close follow-up as our patient had experienced severe pain and distress in the period following the initial treatment. We feel that age and level of activity should also play a role in determining whether surgical repair is required. Surgery should entail complete and rigid repair of the rotator-cuff tendon to its anatomical footprint.



Picture 2: Active abduction of 132°



Picture 3: Active abduction and external rotation

Literature has shown that functional outcomes are improved in patients whose rotator cuffs were repaired before 3 weeks and that better pain relief was obtained if operated before 3 months.¹² Even if the rotator cuff is repaired, Simank⁴ showed that these injuries still had a negative effect on the result of overall treatment⁴ compared to cases where the patient had no tear.

Brachial plexus injury

Very few cases of brachial plexus injury occurring together with a shoulder dislocation and rotator-cuff tear have been reported. Most brachial plexus injuries due to shoulder dislocation are postganglionic, infraclavicular lesions that are in continuity and are caused by stretching.¹³ Identifying the extent of these injuries is important for prognostic reasons as infraclavicular lesions have an excellent prognosis.¹²

Early nerve repair provides the best chance of axonal regrowth in the case of transected nerve injuries or discontinuity lesions

Because shoulder muscle function can be difficult to evaluate clinically, it is suggested that electromyography be performed after 3 weeks in the case of shoulder dislocation in the elderly with palsy or weakness. As could be seen in the reported case, the recovery of function was protracted but eventually good function returned only after 6 months. Intensive physiotherapy is essential to help maintain a good range of motion. A poor prognosis can be expected if motor function has not yet recovered at 3 to 4 months.¹⁴

Brachial plexus injuries also occur in up to 60% of subclavian or axillary-artery ruptures associated with shoulder dislocation in the elderly. Some authors suggest that the brachial plexus should be explored at the initial vascular repair. This early nerve repair provides the best chance of axonal regrowth in the case of transected nerve injuries or discontinuity lesions.

Peripheral nerve injury

The most commonly affected peripheral nerve in shoulder dislocations is the axillary nerve. Peripheral nerve injuries that occur after shoulder dislocation increase in incidence as age increases. Most of these injuries occur due to stretching. Always be aware that a nerve injury can accompany a rotator-cuff tear, which in turn can mask the palsy. Sensory testing in isolation tends to be unreliable. Diagnosis should therefore also be based on weakness, delayed functional return, and electromyography results.

Vascular injury

The incidence of axillary artery injury occurring with an upper limb dislocation (shoulder) is 0.95% according to Sparks *et al.*¹⁷ Over 90% of reported cases of vascular injury following shoulder dislocation occur in patients over the age of 50 years.¹⁶ These vascular injuries occur most often when chronically dislocated shoulders are reduced by closed manoeuvres. The most common site of injury is the third part of the axillary artery. Up to a third of reported cases occur in patients where there is a history of previous dislocation, which may suggest that previous dislocations cause the artery to be fixed by inflammatory tissue in the torn shoulder joint capsule that makes it prone to injury.

The triad of anterior shoulder dislocation, a reduction in amplitude of the radial or brachial pulse and the presence of an expanding axillary mass should be considered pathognomonic of an axillary artery injury.

Associated fractures

The greater tuberosity is an important component in the normal functioning of the shoulder as it serves as an insertion point for the rotator-cuff tendons, which in turn play a big role in stabilising and controlling movements in the shoulder. With displacement, the altered function of the rotator-cuff tendons can lead to a loss of shoulder abduction and strength.

Dimakopoulos and co-authors showed an incidence of 6.6% of greater tuberosity fractures in elderly patients with anterior shoulder dislocation.¹⁹ There is a difference of opinion in the literature on the outcome of nonoperative treatment with some authors, such as Neer,²⁰ stating that fractures displaced by less than 0.5 cm will result in a satisfactory outcome, while others, like Olivier *et al.*,²¹ demonstrate unsatisfactory outcomes in 31% of their patients using Neer's criteria. Young and Wallace also showed that patients with fracture-dislocations progressed more slowly during rehabilitation and experienced more pain with nonoperative treatment.²²

We therefore agree with Dimakopoulos *et al* and feel that anatomic reconstruction of the greater tuberosity and subsequent rotator-cuff repair in this patient population allow for early passive motion and subsequent avoidance of tendon retraction, malunion and chronic pain.

Conclusion

It is clear that shoulder dislocation in the elderly patient is a complex problem with a wide spectrum of associated injuries and complications. Early and accurate diagnosis of these associated injuries can prevent long-term pain and decreased function in the increasingly active older population.

Acknowledgements

The corresponding author wishes to acknowledge financial assistance received from the SA Orthopaedic Association (in the form of the Smith & Nephew travel grant) and Karl Storz Arthroscopy.

References

1. Rowe C. Prognosis in dislocations of the shoulder. *J Bone Joint Surg Am* 1956;**38**:957-77.
2. McLaughlin MC. *Trauma*. Saunders: Philadelphia; 233-96.
3. Groh GI, Rockwood CA. The terrible triad: anterior dislocation of the shoulder associated with rupture of the rotator cuff and injury to the brachial plexus. *J Shoulder Elbow Surg* 1995;**4**(pt 1):51-3.
4. Simank H, Dauer G, Scheider S, Loew M. Incidence of rotator cuff tears in shoulder dislocations and results of therapy in older patients. *Arch Orthop Trauma Surg* 2006;**126**:235-40.
5. Gumina A, Postacchini F. Anterior dislocation of the shoulder in elderly patients. *J Bone Joint Surg Br* 1997;**79**:540-3.
6. Stevens JH. Dislocation of the shoulder. *Ann Surg* 1926;**83**:84.
7. Codman E. *The shoulder*. (2nd edition). Boston: Todd, 1934:262-312.
8. Gumina A, Postacchini R. Anterior dislocation of the shoulder in the elderly patient. *J Bone Joint Surg Br* 1997;**79**:540-3.

9. Penvy T, Hunter R, Freeman J. Primary traumatic anterior shoulder dislocation in patients 40 years of age and older. *Arthroscopy* 1998;**14**:289-94.
10. Itoi E, Tabata S. Rotator cuff tears in anterior dislocation of the shoulder. *Int Orthop* 1992;**19**:240-4.
11. Neviaser RJ, Neviaser TJ, Neviaser JS. Concurrent rupture of the rotator cuff and anterior dislocation of the shoulder in the older patient. *J Bone Joint Surg* 1988;**70A**:1308-11.
12. Berbig R, Weihaupt D, Jurg P, Shahin O. Primary anterior shoulder dislocation and rotator cuff tears. *J Shoulder Elbow Surg* 1999;**8**:220-5.
13. Stayner LR, Cummings J, Andersen J, Jobe CM. Shoulder dislocations in patients older than 40 years of age. *Orthop Clin North Am* 2000;**31**:231-9.
14. Bassett R, Cofield R. Acute tears of the rotator cuff, the timing of surgical repair. *Clin Orthop* 1983;**175**:18-24.
15. Gonzales D, Lopez R. Concurrent rotator-cuff tear and brachial plexus associated with anterior dislocations of the shoulder. *J Bone Joint Surg Am* 1991;**73**:620-1.
16. Rockwood C, Matsen F (eds). *The shoulder* (2nd edition). Philadelphia: WB Saunders; 1998:611-754.
17. Sparks SR, De LaRosa J, Bergan JJ, Hoyt DB, Owen EL. Arterial injury in uncomplicated upper extremity dislocation. *Ann of Vasc Surg* 2000;**14**:110-3.
18. Kelley SP, Hinsche AF, Hossain JFM: Axillary artery transection following anterior shoulder dislocation: classical presentation and current concepts. *Injury, Int J Care Injured* 2004;**35**:1128-32.
19. Dimakopoulos P, Panagopoulos A, Kasimatis G, Syggelos SA, Lambiris E. Anterior Traumatic Shoulder Dislocation Associated With Displaced Greater Tuberosity Fracture: The Necessity of Operative Treatment. *J Orthop Trauma* 2007;**21**:104-12.
20. Neer CS 2nd. Displaced proximal humeral fractures: Classification and evaluation. *J Bone Joint Surg* 1970;**53-A**:1077-89.
21. Olivier H, Duparc J, Romain F. Fractures of the greater tuberosity of the humerus. *Orthop Trans* 1986;**10**:223.
22. Young T, Wallace W. Conservative treatment of fractures and fracture-dislocation of the upper end of the humerus. *J Bone Joint Surg Br* 1985;**67-B**:373-7.